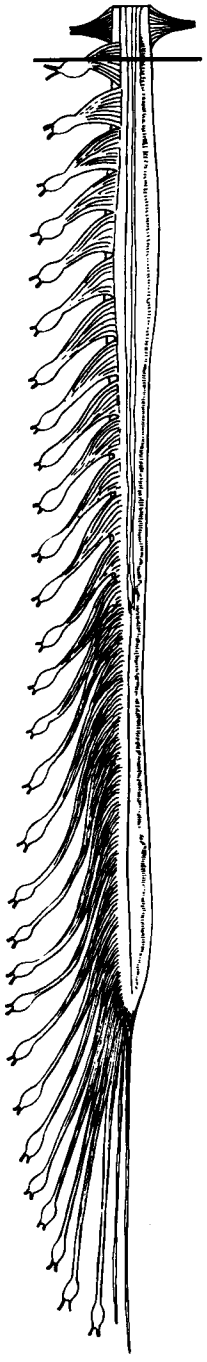

Fig. 38.

Dorsal median sulcus
Ventral white commissure
Gracile fasciculus
Dorsal intermediate sulcus
Cuneate fasciculus
Dorsal root of spinal nerve
Propriospinal tract
Dorsolateral sulcus
Dorsolateral tract (Lissauer's fasciculus) (contains part of the descending spinal trigeminal tract at C_1, C_2, & C_3 levels of the spinal cord)
Substantia gelatinosa
Dorsal spinocerebellar tract
Fascicles of spinal accessory nerve (XI)
Lateral corticospinal tract
Rubrospinal tract
Accessory nucleus (XI)
Ventral spinocerebellar tract
Lateral spinothalamic & spinotectal tracts
Medial motor nuclei: Ventromedial
Spino-olivary & olivospinal tracts
Lateral vestibulospinal tract
Ventral root of spinal nerve
Ventral spinothalamic tract
Medial longitudinal fasciculus (contains medial vestibulospinal tract)
Tectospinal tract
Ventral median fissure
Ventral corticospinal tract

Figure 38. Organization of the white matter: Upper cervical cord (C2)—Weil, 18×