



Planes of Orientation

Ways to Look at the Brain

Psychology 372

Physiological Psychology

Steven E. Meier, Ph.D.

Listen to the audio lecture while viewing these slides or view the video presentation available through Blackboard

1

Psyc 372 – Physiological Psychology

Neural Axis

- Is an imaginary line drawn through the spinal cord and the brain
- Anatomical directions are then based relative to the neural axis.

2


Psyc 372 – Physiological Psychology

Cuts and Locations of Tissue Based on These Cuts

3

Psyc 372 – Physiological Psychology

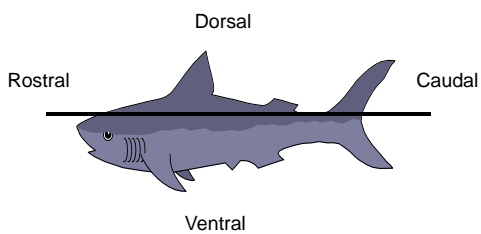
Horizontal or Transverse Cuts



4

Psyc 372 – Physiological Psychology

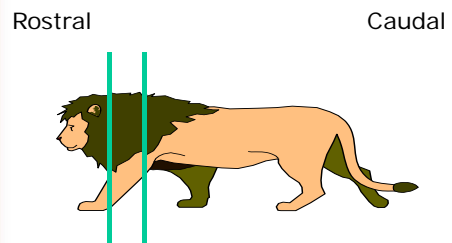
Horizontal Cuts



5

Psyc 372 – Physiological Psychology

Coronal Cuts (Frontal or Transverse Cuts)



6

Axial Organization in Animals

- Rostral - means toward the nose
- Caudal - means toward the tail
- Dorsal - means toward the back
- Ventral - means toward the abdomen


7

Humans

- The long axis flexes between the brainstem and diencephalon

8

Horizontal Cut in the Human Brain



9

Above the Flexure

- Rostral means toward the nose
- Caudal means toward the back of the head
- Dorsal = Superior
 - means above, or toward top of the head
- Ventral = Inferior
 - Means below or toward the Jaw

10

In the Spinal Cord

- Rostral means toward the neck and head
- Caudal means toward the coccyx bone
- Ventral means toward the abdomen
- Dorsal means toward the back

11

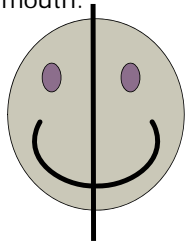
Sagittal Cuts

- Two types
 - Mid-Sagittal
 - Para-Sagittal

12

Mid-Sagittal

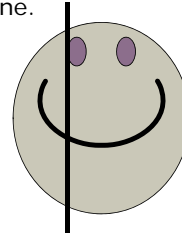
Cut is through the center of the eyes, nose and mouth.



13

Para-Sagittal

Cut is not through the center of the eyes, nose and mouth. Cut moves away from the midline.



14

Other Terms

- Lateral - means to move away from the body midline
- Medial - means to move toward the body midline.
- Ipsilateral: means same side of brain
- Contralateral: means opposite side of brain

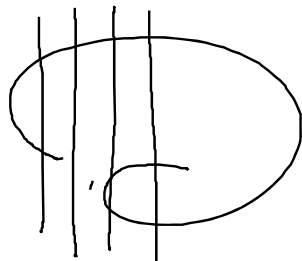
15

Coronal Cuts

- Generally cuts move from front to back
- Is like a slice straight down the body from the top of the head.

16

Coronal Cuts



17